International Journal of Current Medical and Pharmaceutical Research

IJCMPR

ISSN: 2395-6429

Available Online at http://www.journalcmpr.com

DOI: http://dx.doi.org/10.24327/23956429.ijcmpr20170243

RESEARCH ARTICLE

RENAL ARTERY VARIATIONS AND ITS CLINICAL SIGNIFICANCE; A CADAVERIC STUDY

Neeta Chhabra*[1] and Vanadana Tomar[2]

[1]Department of Anatomy, GS Medical College and Hospital Pilkhuwa, Hapur -245304

[2]Department of Anatomy ACMS Delhi Cantt-10

ARTICLE INFO

Article History:

Received 15th June, 2017
Received in revised form 12th July, 2017
Accepted 27th August, 2017
Published online 28th September, 2017

Key words:

Renal artery, variations, vascular, renal transplantation.

ABSTRACT

Introduction: Anatomical variations in the vascular pattern of kidneys have been well documented in medical literature. Normally each kidney is supplied by a single renal artery. Multiple renal arteries are unilateral in approximately 30% of patients and bilateral in approximately 10%.

Aim:To highlight multiple variations in renal vascular pattern in North Indian Population.

Materials & Methods: Renal arterial pattern of a total of 51 kidneys (28 right & 23 left) were studied after careful dissection of the hilar region and variations noted.

Observations& Results: 33(64.7%) kidneys were supplied by a single renal artery. Variations were observed in 18(35.3%) kidneys. Double renal arteries was seen in 13(25.5%) and triple renal arteries in 5(9.8%).In 9(17.6%) specimens, a superior polar artery was observed and in 5(9.8%) kidneys there was an inferior polar artery.

Conclusion: Awareness of variations of renal artery is necessary for surgical management during renal transplantation; repair of abdominal aorta aneurysm, urological procedures and for angiographic interventions. A failure in recognizing these anomalies during renal transplant and kidney retrieval surgeries may lead to severe hemorrhage and graft loss.

INTRODUCTION

The kidneys are one of the vital organs in the human body. They are supplied by renal arteries which are a pair of lateral branches arising from abdominal aorta, just below the origin of the superior mesenteric artery at the level of L2 vertebra. In 70% of cases, there is single renal artery supplying each kidney. The paired renal arteries take about 20% of the cardiac output to supply the kidneys. The right renal artery is longer than the left due to the position of aorta which is nearer to the left of midline. Near the hilum of the kidney, each renal artery divides into anterior and posterior division which further divides into segmental arteries to supply the respective segments of the kidney. Anterior trunk passes in front of the renal pelvis and subdivides usually into four segmental arteries apical, upper and anterior, middle and anterior, inferior. Posterior trunk passes behind the renal pelvis and is continued as posterior segmental artery. These segmental arteries are the end arteries (1). Variations in renal arteries are highly common and include mode of origin, number, course, branching pattern and termination(2). The most common variations are extra renal arteries and early bifurcation. The early branching of renal artery is defined as the branches arising within 15mm from the origin of main renal artery ostium. The incidence is around 10-12%. Insufficient degeneration of mesonephric arteries leads to presence of more than one artery. The incidence of extra renal arteries ranges from 25-40%. Extra renal arteries are further divided into hilar and polar arteries(3). The arteries that arise from the aorta above or below the main renal artery and reach the hilum are called hilar or accessory renal arteries. Accessory renal arteries may also arise from coeliac and superior mesenteric arteries near the bifurcation or from common iliac arteries (1). The arteries that enter the poles are considered as aberrant or polar arteries (3). Aberrant arteries are common in fused kidneys. They perforate the substance of the kidney rather than entering its hilum to supply it. These arteries could arise as high as inferior phrenic artery or as low as internal iliac arteries. They may originate from the aorta, as well as gonadal, common iliac, middle sacral, external or internal iliac or superior or inferior mesenteric arteries. Polar artery can be superior or inferior. Superior renal polar arteries are usually single. They arise as separate branches from the aorta or as branches of the renal, inferior suprarenal, inferior phrenic or superior mesenteric

artery. Inferior polar arteries are also usually single and arise from the aorta or renal artery. They have also occasionally been reported arising from a suprarenal, common iliac or superior mesenteric artery. The inferior polar arteries are sometimes doubled, with one arising from the aorta and the other from the renal artery, or the pair from the either source (4). The presence of additional renal arteries is very probable when the diameter of the main renal artery is less than 4.15 mm. Kidneys presenting a main renal artery greater than 5.5 mm very probably do not present additional renal arteries. So the renal artery diameter is a factor which should be considered as predicting the presence of additional renal arteries (5).Aberrant or accessory renal arteries hold significant importance in diagnostic and therapeutic strategies. Knowing the possibilities of aberrant or accessory renal vessels, provides a better approach to radiological and surgical interventions in cases of nephrectomies, renal tumors, transplants and renal vascular disorders.

MATERIALS & METHODS

The present study was carried out on 51 kidneys of North Indian origin obtained during routine abdominal dissection conducted for medical undergraduates at Department of Anatomy. Hilar region of the kidneys was carefully dissected and cleared and the renal arteries were explored. The arteries of the kidneys were then observed for their number, variation in the branching pattern, and also entry at other points especially the poles. Multiple variations in number and branching pattern of renal arteries were observed. Kidneys with variations were noted and photographed.

OBSERVATION AND RESULTS

The results of the study are depicted as per table below

Table 1. Shows the no. of arteries in the hilum of kidneys and their percentage

Sr No.	No. of arteries	Incidence % (n=51)	Right(n=28)	Left(n=23)
1	One	33(64.7%)	14(27.4%)	19(37.2%)
2	Two	13(25.5%)	11(21.6%)	2(3.9%)
3	Three	5(9.8%)	3(5.9%)	2(3.9%)

In the present study a single artery entering the hilum was seen in 33(64.7%) specimens. 14(27.4%) belonged to right side and 19(37.2%) belonged to left. 18(35.3%) kidneys showed variations in the form of multiple arteries. Double renal arteries were observed in 13(25.5%) kidneys. 11(21.6%) belonged to right side and 2(3.9%) to left. Triple renal arteries were observed in 5(9.8%) specimens, 3(5.9%) belonged to right and 2(3.9%) to left. Incidence of multiple renal arteries was more on right side.

Table 2. Shows the no. of arterial divisions in the hilum and their percentage

Sr No.	No. of arterial divisions	Incidence% (n=51)	Right (n=28)	Left (n=23)
1.	One	2(3.9%)	2	-
2.	Two	2(3.9%)	1	1
3.	Three	5(9.8%)	4	1
4.	Four	10(19.6%)	5	5
5.	Five	17(33.3%)	8	9

In the present study we observed a maximum of seven divisions emerging from the main arterial trunk. The most common was five arterial divisions found in 17(33.3%) specimens. Next in order of frequency was six in 12(23.5%) specimens followed by 4 divisions in 10(19.6%) kidneys.

Table 3. Shows the distribution of aberrant arteries and their percentage

Sr No.	Aberrant/ Polar artery	Incidence% (n=51)	Right (n=28)	Left (n=23)
1.	Superior	9(17.6%)	5	4
2.	Inferior	5(9.8%)	4	1

Aberrant or Polar artery was observed in 14(27.4%) kidneys. In 9(17.6%) specimen superior polar artery was observed while in 5(9.8%) inferior polar artery was found. The frequency of aberrant arteries was more on right side.

Table 4. Shows the branching pattern in the hilum and their percentage

Sr No.	Arterial division pattern	Incidence% (n=51)	Right (n=28)	Left (n=23)
1.	Fork pattern	42(82.3)%	5	4
2.	Step Ladder pattern	9(17.7%)	4	1

42(82.3%) kidneys showed a fork type branching pattern and in 9(17.7%) the branching pattern was of ladder type. Fork pattern of branching was more common.

Fig 1&2 Shows two and three arteries entering the renal hilum

Fig 3& 4 Shows fork pattern and step ladder pattern of branching of renal arteries

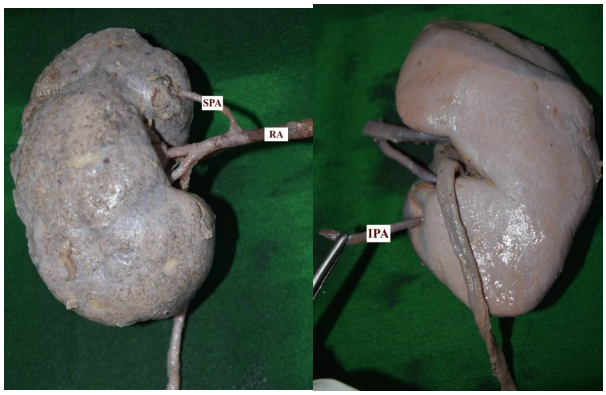

Fig 5&6: Shows Superior and Inferior polar arteries

DISCUSSION

Most of the abnormalities in the renal vasculature is due to abnormal rotation or due to the various developmental positions of kidney. The kidneys begin their development in the pelvic cavity. During further development they ascend to their final position in the lumbar region. When the kidneys are located in the pelvis, they are supplied by branch of internal iliac artery or common iliac arteries. While the kidneys ascend to lumbar region, their arterial supply also shifts from common iliac artery to abdominal aorta (6). The various types of renal arteries (accessory, additional and aberrant), their positions, method of entry to the kidney and segmentation have been studied extensively by a number of authors (7,8). Accessory renal arteries constitute the most common, clinically important vascular variant and are seen in up to one-third of patients (9). They are usually unilateral in 30% and bilateral in approximately 10%. Accessory renal arteries usually arise from the Aorta or Iliac arteries anywhere from the level of T11-L4 vertebra. In rare case they can arise from the lower thoracic or mesenteric arteries. The most common variation of an accessory renal artery may enter through the hilum or through the surfaces of the kidney. Accessory renal vessels (perforating artery) to the pole are usually smaller than accessory hilar renal vessels, which are typically equal in size to single renal artery (10).According to Graves any artery arising from the aorta in addition to the main renal artery should be named 'accessory' and the renal arteries arising from sources other than the aorta should be called 'aberrant (11). Satyapal *et al* defined accessory renal artery as a branch from aortic branches and additional renal artery as branch of aorta (12). Rao and Rachana defined an accessory renal artery as the one that is present in addition to the main renal artery and enters the kidney through hilum whereas aberrant renal artery supplies the kidney without entering its hilum (2).

In the present study single renal artery was seen in 33(64.7%) kidneys while 18(35.3%) showed presence of an additional renal artery. 13(25.5%) specimens had double renal arteries while triple renal arteries were observed in 5(9.8%) kidneys. The incidence of multiple vessels was more common on the right side. Bordei *et al* analyzed 272 kidneys for a study of renal vascularization and identified 54(20%) double renal arteries and 3(1.1%) triple renal arteries (13). Hemanth Kommuru *et al* studied 182 kidneys. 34 kidneys showed presence of one additional artery, whereas two additional arteries were seen in 18 kidneys, extra artery was present unilaterally in 6 cadavers and bilaterally in 20 cadavers. 23 showed presence of superior polar artery and 29 showed inferior polar artery. They also mentioned that in one of the cases the aberrant (accessory) renal artery was a branch of superior mesenteric artery (14). Ozkan *et al*, in their angiographic study of 855 patients found that 24% of patients had more than one renal artery. The incidence was more common on the right side (3). In a study conducted by Dhar and Lal accessory renal arteries were observed in 20% of specimens. The anomaly was unilateral in 15% cases and bilateral on 5% of cases (15). K S Satyapal found that out of 130 renal angiograms and 32 cadavers, kidneys showed presence of one additional renal artery in 23.2% and two additional renal arteries in 4.5%. They were seen more commonly on left side 32% as compared to 23.3% on right side (12). Saldarriaga *et al* reported 97(24.9%) out of 390 kidneys having additional arteries; 87 (22.3%) had one additional artery and 10 (2.6%) had two additional arteries (5). The findings of the present study are more or less in concurrence with most of the previous studies on renal vasculature. In the present study aberrant or polar artery was observed in 14 (27.4%) kidneys. Nine (17.6%) aberrant arteries were observed entering the kidneys through the superior pole. 5 were on right side and 4 on left. In 5(9.8%) specimens the aberrant branch was entering through the inferior pole. 4 were on right and one was on left. Sampaio *et al* in 1992 observed superior polar artery originating from the aorta in 6.8% of specimens. They found two hilar with one superior pole extra hilar branch in 9 out of 266 kidneys (16). Bordei *et al* in 2007 reported that in 5 out of 54 cases (9.25%) the supplementary renal artery entered the kidney through the superior pole (13). Budhiraja *et al* in 2008 observed that 10.7% cases of superior polar artery originated directly from the abdominal aorta as an additional renal artery(17). Shakuntla *et al* in their study observed 12 polar arteries out of which 10 were on left side and 2 were on right side(18)· Incidence of inferior polar accessory arteries is twice to the superior polar arteries. In the present study superior polar artery was more frequent.

Shoja *et al* studied the variation in perihilar branching pattern and morphology of the main artery. They classified the branching as ladder and fork patterns. The pattern where there were sequential branching points was termed ladder type. The pattern with a common branching type was termed the fork type. The fork was either duplicate or triplicate depending on the no. of branches. They observed that the main artery was of the fork pattern in 92.6% (75), duplicated in 80.2%(65), triplicated in 12.4%(10) and ladder pattern was present only in 7.4% specimens (19). In the present study fork pattern was observed in 42(82.3%) and ladder pattern in 9(17.7%). The fork pattern was more frequent than the ladder pattern. The anterior division often showed the fork pattern. Hence it can be considered that branching outside the hilum is a normal pattern where the arteries divide to go to the respective segments.

CONCLUSION

In view of constantly increasing renal transplantations and kidney retrieval surgeries, thorough knowledge of variations in vascular pattern is important to avoid iatrogenic injuries during these procedures. Aberrant or accessory arteries may be inadvertently damaged during renal surgery and their presence must be considered in evaluating a donor kidney for possible renal transplantation.

References

1. Standring S. Gray's Anatomy. The Anatomical Basis of Clinical Practice. 40th ed. Edinburgh: Churchill Livingstone. 2009; 1086-1089.
2. Rao TR. Rachana. Aberrant renal arteries and its clinical significance: a case report. *Int J Anat Var* 2011; 4: 37-9.
3. Ozkan U, Oguzkurt L, Tercan F, Kizilkiliç O, Koç Z, Koca N. Renal artery origins and variations: angiographic evaluation of 855 consecutive patients. *Diagn Interv Radiol* 2006; 12:183-6.
4. Bergman RA, Thomson SA, Afifi AK, Saadeh FA. Compendium of Human Anatomic Variation. Baltimore, Urban & Schwarzenberg 1988; 81-83.
5. Saldarriaga B, Pinto SA, Ballesteros LE. Morphological expression of the renal artery:a direct anatomical study in a Colombian half-caste population. *Int J Morphol*

2008; 26 (1):31-8.
6. Moore K L and PerSand TVN. The Developing Human. Saunders, an Imprint of Elsevier. 7th ed. 2003:293.
7. B J Anson, GA Richardson, W L Minear. Variations in the number and arrangements of the renal blood vessels, a study of the blood supply of four hundred kidneys. *J Urol* 1936; 36:211-19.
8. D Sykes. The arterial supply of the human kidney with special reference to accessory arteries. *British journal of Surgery*1963; 50:368-74.
9. Stephens FD. Ureterovascular hydronephrosis and the aberrent renal vessels. *J.Urol* 1982; 128:984-87.
10. Kadir S *et al*. Angiography of the kidneys, Diagnostic angiography. Philadelphia: Saunders.1986; 445-95.
11. Graves FT. The aberrant renal artery. *J Anat* 1956; 90:553-8.
12. Satyapal KS, Haffejee AA, Singh B, Ramsaroop L, Robbs J V, Kalideen JM. Additional renal arteries; Incidence and morphometry. *Surg Radiol Anat* 2001; 23(1):33-48.
13. Bordei P, Sapte E, Iliescu D. Double renal arteries originating from the aorta. *SurgRadiol* 2004; 26(6): 474-9.
14. Hemmanth Kommuru, Sreelekha D, Jothi SS, Rajeswararao N, Sujatha N. Presence of renal artery variations and its surgical correlation. *IJCMR* 2012;3(5):176-9.
15. Dhar P, Lal K. Main and accessory renal arteries, a morphological study. *Ital J Anat Embryo* 2005; 110:101-10.
16. Sampaio FJ, Passos MA. Renal arteries: anatomic study for surgical and radiological practice. *Surg Radiol Anat* 1992; 14:113-17.
17. Budhiraja V, Rastogi R, Asthana A K. Variant origin of superior polar artery and unusual hilar branching pattern of renal artery with clinical correlation. *India Folia Morphology* 2008; 70(1):24-8.
18. N Shakuntala Rao, Krishna Kishore, Sujatha K, H RKrishna Rao. Extra hilar branching of renal arteries: an anatomical study. *Int J Anat Res* 2015;3(4):1568-72.
19. M M Shoja, R S Tubbs, A Shakeri, M R Ardalan, H T Khosroshahi, W J Oakes. Perihilar branching patterns and morphologies of the renal artery: a review and anatomical study. *Surg Radiol Anat* 2008; 30(5):375-82.

****