ISSN: 2395-6429

INTERNATIONAL JOURNAL OF CURRENT MEDICAL AND PHARMACEUTICAL RESEARCH

IJCMPR

Available Online at http://www.journalcmpr.com

DOI: http://dx.doi.org/10.24327/23956429.ijcmpr20170069

RESEARCH ARTICLE

CONTRAST ENHANCED CT EVALUATION OF SOLID RENAL MASSES

Bhoomi Angirish*., Chandresh Bharada., Harshad Shah and Rasesh Vyas

Department of Radiology Resident, c.u. Shah Medical College, Surendranagar, Gujarat

ARTICLE INFO

Article History:

Received 13th February, 2017
Received in revised form 8th March, 2017
Accepted 5th April, 2017
Published online 28th May, 2017

Key words:

Renal masses, CECT, Renal cell carcinoma, Renal metastasis, Angiomyolipoma, Hematoma.

ABSTRACT

Objective: The objective of the study was to evaluate solid renal masses using CECT and to differentiate them on the basis of their attenuation and contrast enhancement characteristics.

Materials And Methods: The present study included 60 patients. The study was conducted from December 2014 to December 2016. Somatom Emotion 16 slice CT machine was used. All patients were evaluated with detailed history and clinical reports.

Results: Out of 60 patients, 33 patients had benign etiology. Rest 27, had a malignant etiology of the renal mass. There were 20 cases of renal cell carcinoma with the most common age group of 50-60 years affected by RCC. Benign masses included angiomyolipoma (6.6%), oncocytoma (3.3%), renal abscess (18.3%), hematoma (13.3%).

Conclusion: For a suspected renal mass, contrast enhanced CT performed in corticomedullary, nephrogenic and excretory phases play a major role in defining the characteristics of the lesion.Renal neoplasm shows greater enhacement in nephrogenic phase compared to corticomedullary phase. CT helps to determine the perinephric extension, invasion into renal vein and IVC, lymph node assessment and evaluation of distant metastasis. Pattern of enhancement of benign masses depends on the etiology. Imaging of renal masses includes accurate characterization of the lesion, assistance with treatment planning, and evaluation of treatment response.

INTRODUCTION

The incidence of renal cancer has increased from 7.1 to 10.8 cases per 100,000 patients between1983 to 2002[1]. Therefore cost effective imaging strategies are necessary to identify clinically significant renal masses. The introduction of helical CT has created many important advances in detection and characterisation of renal masses and is considered to be the state of art in the evaluation of abdomen. It is widely accepted as a preferred imaging technique for suspected renal tumours, staging, detection of metastasis because of its low cost, high accuracy and ready accessibility.

The commonest space occupying renal lesion is a simple cyst with incidence of 25-50% after the age of 50 years. Solid malignant masses most frequently encountered in clinical practice are renal cell carcinoma, urothelial carcinoma, lymphoma and metastasis, whereas the most frequently encountered benign solid renal masses are angiomyolipoma, oncocytoma and inflammatory pseudotumours/ pseudolesions.

MATERIALS AND METHODS

In the present study, contrast enhanced CT scan was performed on 60 patients using SIEMENS 16 slice MDCT Somatom Emotion machine. The study was conducted from December 2014 to December 2016. Detailed history was taken and relevant clinical reports were also reviewed. Plain CT scan followed by Contrast enhanced CT using non-ionic contrast medium with dose calculated according to body weight (300 mg iodine / kg body weight) was performed. CECT included the corticomedullary (40 sec), nephrogenic (100-120 sec) and delayed phases (5-7 min) .

RESULTS

Table 1 Diagnosis

Diagnosis	No. Of cases	Percentage
Renal cell carcinoma	20	33.3
Renal abscess	11	18.3
Renal metastasis	6	10
Hematoma	8	13.3
Renal angiomyolipoma	4	6.6
Renal oncocytoma	2	3.3
Xanthogranulomatous pyelonephritis	3	5
Urothelial carcinoma	1	1.6
Renal pseudotumour	5	8.3

Table 2 Clinical Presentation

Complain	Number	Percentage
Hematuria	22	36.6
Loin pain	18	30
Weight loss	5	8.3
Trauma	8	13.3
Fever	5	8.3
Asymptomatic	2	3.3

Table 3 Sex Distribution

Gender	Number
Males	37
Females	23

Table 4 Age Distribution Of Patients

Age distribution	Number
20-30	4
30-40	8
40-50	8
50-60	14
60-70	11
70-80	10
80-90	5

Table 5 Age Distribution Of Renal Cell Carcinoma

Age distribution	Number
20-30	0
30-40	2
40-50	3
50-60	8
60-70	4
70-80	2
80-90	1

Table 6 Severity of Lesion

Type of lesion	Number
Benign	33
Malignant	27

DISCUSSION

Age incidence: In the present study, age groups from 20 to 90 years were included. Renal cell carcinoma (RCC) was found to be more common in the age group of 50-60 years.

Sex incidence: Out of 60 patients, incidence of renal masses was more common in males (61.6%). In a study conducted by Hes O *et al*, RCC is more common in men (1.6:1, male/female ratio)[2].

Clinical presentation: Hematuria (36.6 %) followed by loin pain (30%) was the most common presenting complain.

Malignant renal masses: Out of 60 renal space occupying masses, 27 were found to be malignant.

Renal cell carcinoma: In our study, 20 cases out of 60 were diagnosed as RCC. The World Health Organisation classification subdivides RCC into histologic groups- clear cell RCC (accounting for 70% to 75%), papillary RCC (10% to 21%), chromophobe RCC (5%) [3]. Patients with localised disease have 92% 5-year survival, whereas this decreases to 65% for those with regional metastasis, and 12% for patients with distant metastatic disease[13].

***Metastases*:** There were 6 cases of metastases. In our study, the most common primary for metastases to kidney was found to be lung followed by breast. Radiologically, metastases were usually multifocal; however, metastases arising from colon, lung, and breast carcinoma were sometimes large, solitary, and otherwise indistinguishable from primary renal cell carcinoma[4]. Renal metastases occurs more commonly at the junction of renal cortex and medulla, often showing ill-defined borders and low-level enhancement, except in the case of hypervascular primary tumours (eg RCC, thyroid, choriocarcinoma). These features may help to suggest the diagnosis, and differ from the most common well-defined appearance of cortical based RCC, although a definitive diagnosis may require biopsy [13].

Urothelial Carcinoma: There was 1 case of urothelial carcinoma of renal pelvis in our study. Median age at diagnosis is 60 years , with approximately 2:1 male/ female ratio, and hematuria being the most frequent presentation [13].During the excretory phase, early transitional cell carcinoma is typically seen as small filling defects, a mass lesion, or circumferential wall thickening in the urothelial wall. The hallmark of TCC is multiplicity and recurrence which requires bladder surveillance in the follow up of these patients [12].

***Angiomyolipoma*:** In our study, there were 4 patients of angiomyolipoma (AML). Angiomyolipoma is the most common benign solid renal neoplasm observed in clinical practice [6]. Most angiomyolipomas are asymptomatic with an incidence approaching 13 per 10,000 adults. They are much more prevalent in patients with tuberous sclerosis, where they often are accompanied by cysts and occasionally by renal cell carcinoma.[5] . The hallmark pathology feature of classic angiomyolipoma is abundant fat. On unenhanced CT, the presence of regions of interest (ROI)-containing attenuations less than −10 HU allows the confident identification of fat. The CT appearance of a classic angiomyolipoma varies due to variable amounts of fat, blood vessels, and smooth muscle components of the neoplasm[6].

Renal oncocytoma: In our study, there are 2 cases (3.3%) of oncocytoma. Renal oncocytoma is a benign renal tumour, accounting for approximately 3–7 % of all renal tumours. Typical imaging findings of renal oncocytoma are described as a homogeneous hypervascular mass with subsequent washout in the delayed phase. A central scar is a characteristic finding, especially in a large oncocytoma[7]. Kim *et al* found that segmental enhancement inversion based on the corticomedullary and early excretory phase was a characteristic enhancement pattern of oncocytoma [8].

Renal abscess: Constituted 18.3% of the cases of our study. Most patients presented with fever and loin pain. CT shows a thick walled lesion with air foci within. The surrounding parenchyma appears hypoattenuating. There is associated thickening of gerota's fascia and perinephric stranding and fluid collection.

***Renal hematoma*:** In our study, there were 8 patients with renal hematoma. 6 had history of trauma. Unenhanced CT plays a major role in identification of hyperattenuating hematoma (HU 60-80). Regarding etiology of spontaneous perirenal hematoma, meta-analysis done by Zhang *et al*. found that 61.5% cases were due to tumors (31.5% malignant and 29.7% benign),17% cases were due to vascular disease, 2.4% cases were due to infection, and in 6.7% cases it was idiopathic[9].

Renal trauma is graded as:

Grade I- account for approximately 80% of renal injuries, are characterized by contusion and nonexpanding subcapsular hematoma without parenchymal laceration.

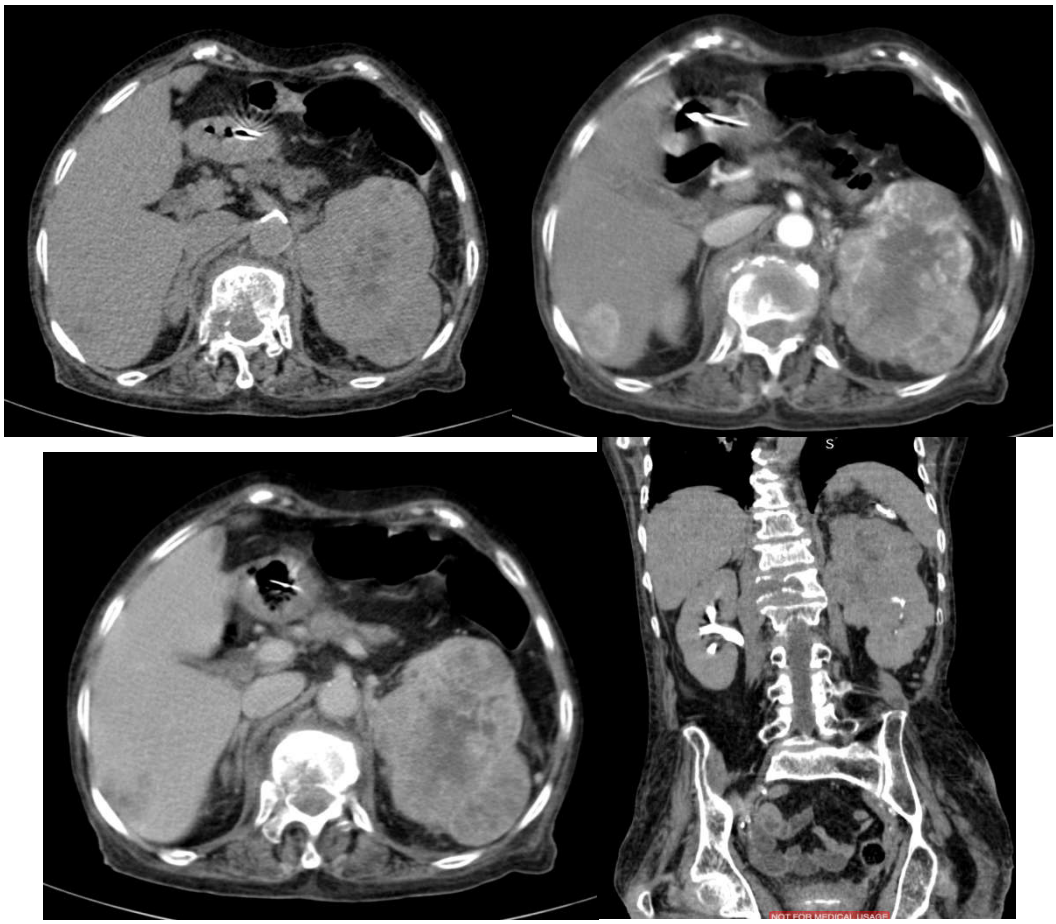

Image 1 (a-d) shows well defined exophytic mass arising from left kidney which shows intense enhancement in arterial phase and washout of contrast in delayed phase.Similar contrast characteristics lesion is seen in liver . Findings are suggestive of Renal cell carcinoma with liver metastasis.

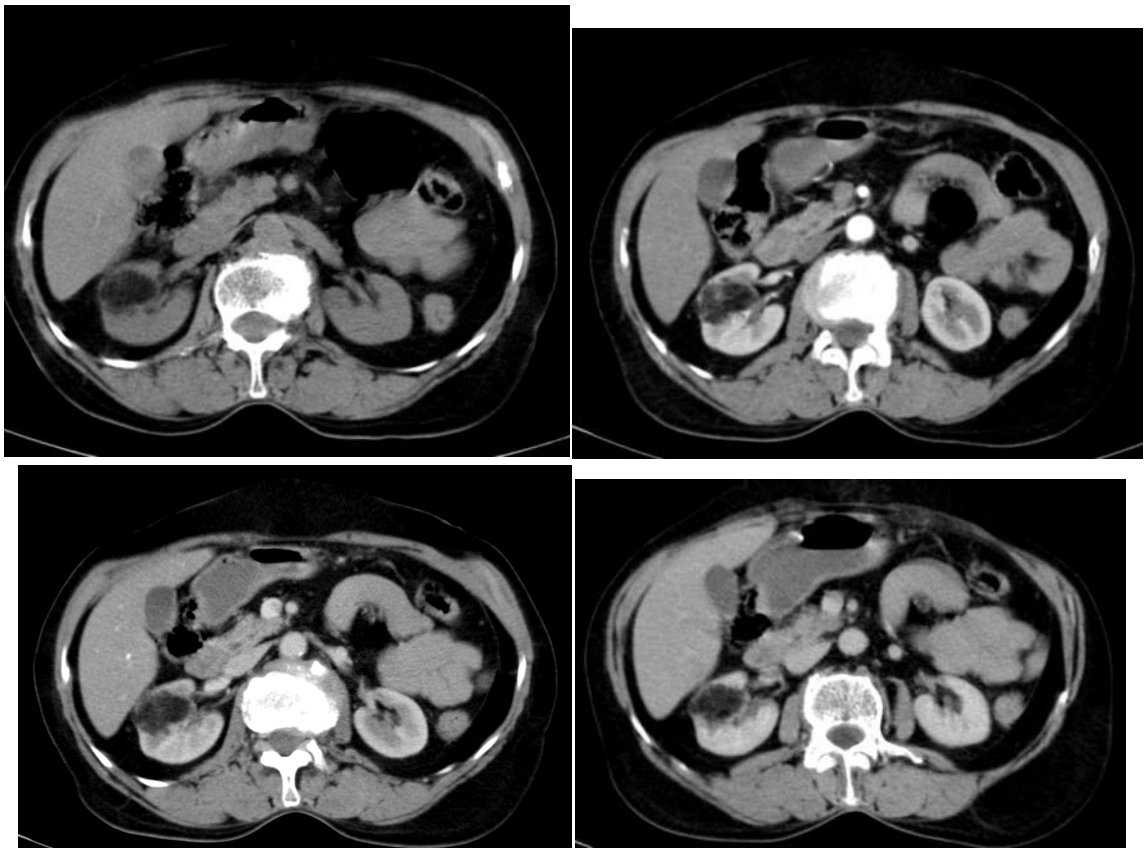

Image 2 (a-d) shows a well defined fat containing lesion which shows heterogeneous enhancement in arterial phase. Findings are suggestive of angiomyolipoma.

Imgae 3 (a& b): Enlargement of the right kidney with multiple large renal calculi and few ill-defined heterogenoushypodense areas. The findings are suggestive of Xanthogranulomatous pyelonephritis.

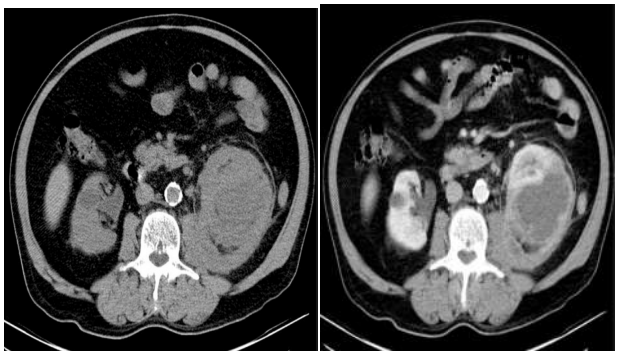

Image 4 (a & b) shows Cystic nonenhancingmultiloculated mass involving the renal parenchyma in the middle and lower third of the left kidney with perinephric fat stranding. The findings are suggestive of Renal abscess.

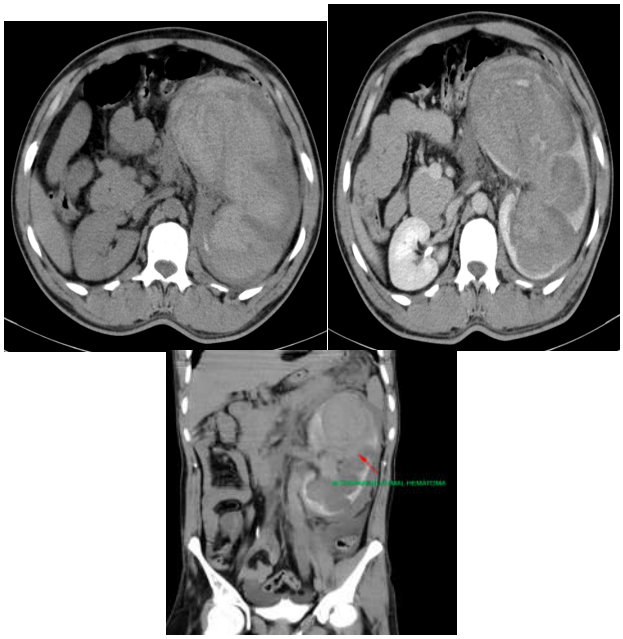

Image 5 showsIll defined non-enhancing heterogenous predominantly hyperdense areas (HU 40-60) in parenchyma of left kidney following trauma suggestive of Intraparenchymal Hematoma.

Grade II – Non-expanding perinephric hematoma confined to the retroperitoneum and cortical laceration < 1cm deep without involvement of the collecting system.

Grade III- – Non-expanding perinephric hematoma confined to the retroperitoneum and cortical laceration > 1cm deep.

Grade IV – lacerations extending through the collecting system and damage of major renal vessels.

Grade V- shattered or devascularized kidney [10].

***Xanthogranulomatous pyelonephritis*:** In our study, there were 3 patients of xanthogranulomatous pyelonephritis (XPN). XPN is an uncommon form of granulomatous inflammation characterized by destruction of renal parenchyma and replacement by solid sheets of lipid laden macrophages. Usually there is a staghorn calculus within a nondilated encased renal pelvis and the renal parenchyma is replaced by multiple water density masses representing dilated calyces and abscess cavities which show prominent wall blush on enhanced studies[11].

***Renal pseudotumour*:** In our study, there were 5 cases of renal pseudotumour. Developmental renal pseudotumours include persistant columns of Bertin, dromedary humps, persistant fetal lobulations. These are easily differentiated from true renal masses by characterization of normal renal parenchyma on imaging[13].

CONCLUSION

- For a suspected renal mass, contrast enhanced CT performed in corticomedullary, nephrogenic and excretory phases play a major role in defining the characteristics of the lesion.
- Renal neoplasm shows greater enhacement in nephrogenic phase compared to corticomedullary phase.
- Renal pseudotumours are best evaluated in corticomedullary phase.
- CT helps to determine the perinephric extension, invasion into renal vein and IVC, lymph node assessment and evaluation of distant metastasis.
- Pattern of enhancement of benign masses depends on the etiology.
- Imaging of renal masses includes accurate characterization of the lesion, assistance with treatment planning, and evaluation of treatment response.

References

1. Kutikov A, Fossett LK, Ramchandani P, *et al*. Incidence of benign pathologic findings at partial nephrectomy for solitary renal masses presumed to be renal cell carcinoma on preoperative imaging. *Urology* 2006;68(4):737-40
2. Hes O, Michal M, Sima R, *et al*. Renal oncocytoma with and without intravascular extension into the branches of renal vein have the same morphological, immunohistochemical, and genetic features. *Virchows Arch* 2008; 452(2):193-200.
3. Gudbjartsson T, Hardarson S, Petursdottir V, *et al*. Renal oncocytoma: a clinicopathological analysis of 45 consecutive cases. *BJU Int* 2005; 96(9):1275-9.
4. P L Choyke, E M White, R K Zeman, *et al*. Renal metastases: clinicopathologic and radiologic correlation. *RSNA Radiology*; 162(2).
5. Eble JN. Angiomyolipoma of kidney. *SeminDiagnPathol.* 1998; 15 (1): 21-40.
6. Masahiro Jinzaki, Stuart G. Silverman, Hirotaka Akita, *et al*. Renal angiomyolipoma: a radiological classification and update on recent developments in diagnosis and management. *Abdominal Imaging* 2014; 39(3):588-604.
7. KouseiIshigami, Aaron R. Jones, Laila Dahmoush, *et al*. Imaging spectrum of renal oncocytomas: a pictorial

review with pathologic correlation. *Insights imaging* 2015; 6(1):53-64.

8. Kim JI, Cho JY, Moon KC, *et al*. Segmental enhancement inversion at biphasic multidetector CT: characteristic finding of small renal oncocytoma. *Radiology* 2009; 252(2):441-448.
9. Zhang JQ, Fielding JR, Zou KH. Etiology of spontaneous perirenalhemorrhage: A meta-analysis. *J Urol* 2002; 167:1593-6.
10. Park SJ, Kim JK, Kim KW et-al. MDCT Findings of renal trauma. *AJR Am J Roentgenol* 2006;187 (2): 541-7.
11. Stanford M. Goldman, David S. Hartman, Elliot K. Fishman, *et al*. CT of xanthogranulomatous pyelonephritis – Radiologic Pathologic correlation. AJR 1984; 141:963-969.
12. Vikram R, Sandler CM, Ng CS. Imaging and staging of transitional cell carcinoma: part 2, upper urinary tract. *AJR Am J Roentgenol* 2009; 192 (6): 1488-93.
13. Fernado U. Kay, Ivan Pedrosa. Imaging of solid renal masses. *Radiology clinics of North America* 2017; 55: 243-258.

****